

Reverse Shoulder Prosthesis for Acute Four-Part Fracture Tuberosity Fixation Using a Horseshoe Graft

Brian L. Badman, MD* and Jonathan C. Levy, MD†

Abstract: Since Neer's first description, many authors have advocated the use of hemiarthroplasty for most 4-part fractures owing to the risk of avascular necrosis of the humeral head. Results of hemiarthroplasty, however, have shown to be unreliable, especially in patients older than 75 years. Recently, the use of the reverse shoulder replacement has been advocated as an alternative solution, as functional recovery may be possible without anatomic tuberosity healing. Preliminary results have been rather encouraging, with several reports of consistent improvement of both pain relief and function. Because restoration of external rotation is best achieved with tuberosity healing, emphasis has been placed on tuberosity repair. The purpose of the current paper was to describe a reliable and reproducible technique for managing 4-part proximal humeral fractures with reverse shoulder arthroplasty using a humeral head horseshoe graft to augment secure tuberosity fixation. Together with a prosthesis that uses a more anatomical center of rotation, this technique provides a means for anatomic restoration of the tuberosities and minimizes the risk of tuberosity migration associated with current prostheses.

Key Words: reverse shoulder arthroplasty, four-part proximal humeral fracture, tuberosity fixation

(*Tech Should Surg* 2009;10: 76–82)

Optimal management of displaced fractures of the proximal humerus remains controversial. One of the most difficult challenges rests in the treatment of elderly patients with 4-part fractures. Neer¹ introduced the concept of using a hemiarthroplasty to manage patients with 4-part fractures. Although his results were quite promising, reliable functional improvement has not been consistently reproduced.^{2–7}

Patients older than 70 years who were treated with a hemiarthroplasty for 4-part fractures of the proximal humerus have been shown to have lower functional scores and overall satisfaction ratings.^{2,7} Poor bone quality and inability to adhere to the strict postoperative protocol may contribute to high rates of malunion, nonunion, or resorption of the tuberosities.^{3,8} In fact, the results of hemiarthroplasty in the elderly population are so unreliable that some have considered accepting the functional limitations expected from nonoperative treatment.^{2,4} For these reasons, the reverse shoulder replacement has been pro-

posed as a reliable treatment option in these patients. Using a reverse arthroplasty, patients may regain a reasonable amount of function and thereby preserve their ability to perform activities required for independent living.^{9–11} Restoration of external rotation depends on the healing of the greater tuberosity segment.⁹ Secure tuberosity fixation is therefore critical. The purpose of this paper was to describe a reproducible surgical technique used to perform reverse shoulder arthroplasty for 4-part fractures in the elderly population using a horseshoe graft to augment secure fixation of the tuberosities.

MATERIALS AND METHODS

Initial Evaluation

A thorough history and a physical examination are essential in all patients being considered for operative intervention. Mechanism of injury and previous history of shoulder pain or loss of function are important factors to be considered. A careful evaluation of the neurovascular function of the extremity is essential because suprascapular and/or axillary nerve injuries have been reported in up to 82% of displaced proximal humerus fractures and associated axillary arterial injuries can occur.^{12,13} Preoperative imaging includes a Neer trauma series, including anteroposterior and lateral views in the scapular plane and an axillary view.¹⁴ A computed tomographic scan may be useful to gain a better understanding of the fracture anatomy, articular congruity, and tuberosity integrity. In cases where glenoid arthritis, glenoid fractures, or glenoid incongruity is present, the computed tomographic scan also helps to better plan proper positioning of the glenosphere component intraoperatively. Magnetic resonance imaging has not proved very useful in the acute fracture setting. Patients being considered for a reverse shoulder arthroplasty should be older than 70 years with a 4-part proximal humerus fracture. Additional relative indications include elderly patients with inadequate social structure for the extensive rehabilitation required after hemiarthroplasty and patients with acute proximal humerus fractures and previous rotator cuff deficiency.

SURGICAL TECHNIQUE

Anesthesia

The patient is administered a single-shot interscalene block to decrease the amount of general anesthetic required and to provide improved initial postoperative pain control. The endotracheal tube should be taped to the contralateral side of the patient's mouth to prevent inadvertent dislodgement during retractor placement and to avoid interference with the surgical field.

Approach

The patient is positioned in an upright beach-chair position with the head firmly secured and the entire operative extremity draped free. A standard deltopectoral approach is used for exposure. The cephalic vein is identified and routinely taken medially with the pectoralis to reduce inadvertent injury during

From the *OrthoIndy, Brownsburg, IN; and †Holy Cross Orthopaedic Institute, Fort Lauderdale, FL.

In support of their research for the preparation of this paper, none of the authors received grants or outside funding. The authors received payments or other benefits or had a commitment or agreement that such benefits will be provided by a commercial entity (DJO Orthopaedics, Austin, Tex). There was no commercial entity paid or directed, or agreed to pay or direct, any benefits to any research fund, foundation, educational institution, or other charitable or nonprofit organization with which the authors are affiliated or associated.

Reprints: Brian Badman, MD, OrthoIndy, 7950 OrthoLane, Brownsburg, IN 46112 (e-mail: blbadman@yahoo.com).

Copyright © 2009 by Lippincott Williams & Wilkins

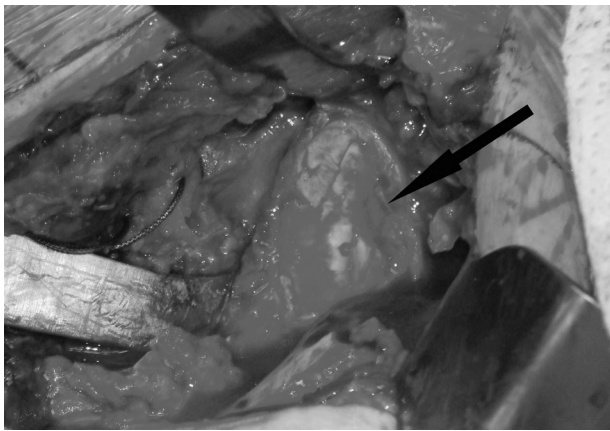


FIGURE 1. Typical surgical exposure with 4-part fracture (arrow pointing at glenoid).

retractor placement. The clavipectoral fascia is released, and typically, fracture hematoma is encountered and evacuated. The subdeltoid and subacromial spaces are then developed, and a Browne deltoid retractor (Innomed, Savannah, Ga) is carefully placed behind the greater tuberosity to facilitate exposure. The subcoracoid space is developed next, and the axillary nerve is palpated for identification at the lower margin of the subscapularis. The biceps tendon is palpated deep to the pectoralis major muscle at its attachment site on the humerus. Fracture hematoma can oftentimes obscure normal anatomy, and identification of the biceps tendon can assist in proper orientation. In 4-part fracture patterns, the fracture line routinely propagates through the upper lateral biceps groove and will cause a split in a portion of the supraspinatus tendon. This split can be used to further allow for intrarticular exposure of the head fragment and release of the biceps tendon off the supraglenoid tubercle. This split can be extended to the level of the glenoid, allowing complete mobilization of the greater and lesser tuberosity fragments. A subpectoral biceps tenodesis is then routinely performed.

With the release of all spaces and adequate debridement of fracture hematoma, the tuberosity integrity and fracture pattern are assessed. To mobilize the tuberosity fragments, a Krackow suture is placed with a no. 2 FiberWire (Arthrex, Naples, Fla) in the substance of the subscapularis and infraspinatus tendons. This allows the surgeon the ability to gain control of the lesser and greater tuberosity fragments. The head fragment is removed with a Kocher clamp and saved for later use as a structural graft

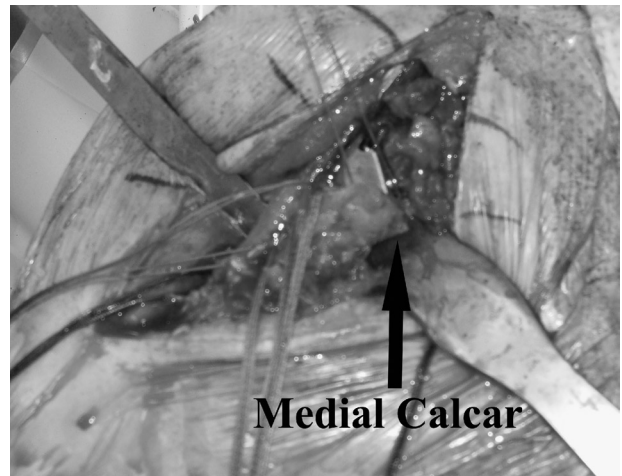


FIGURE 3. Appropriate height of humeral stem. When the medial calcar is intact, the stem should be placed at the level of the calcar fracture.

(horseshoe graft). In situations of fracture dislocations where the head is typically displaced anteriorly and medially to the glenoid neck, care should be given to avoid overzealous pulling and prevent inadvertent injury to the neurovascular structures lying in close proximity.

Glenoid Preparation

Next, the glenoid is exposed via a 360-degree periglenoid capsular release. Visualization is typically not difficult in the fracture setting (Fig. 1). Our typical sequence of retractor placement is to first place a small pointed Hohmann (DJO Surgical, Austin, TX) above the supraglenoid tubercle at the posterosuperior glenoid margin. A Fakuda retractor (DJO Surgical, Austin, TX) or posterior glenoid retractor can then be placed posteriorly. A third retractor is then placed anteriorly along the glenoid neck after the plane between the subscapularis and capsular-labral complex is identified. The labrum is then circumferentially released off the glenoid. Care should be taken at the inferior aspect of the glenoid to avoid injury to the axillary nerve, and oftentimes, a retractor is placed above the nerve for protection.

The current technique for glenoid preparation relates to the DJO Surgical Reverse Shoulder Prosthesis (DJO Surgical, Austin, Tex). A centering hole is drilled using a 2.0-mm drill with a 15-degree inferior tilt followed by placement of a 6.5-mm

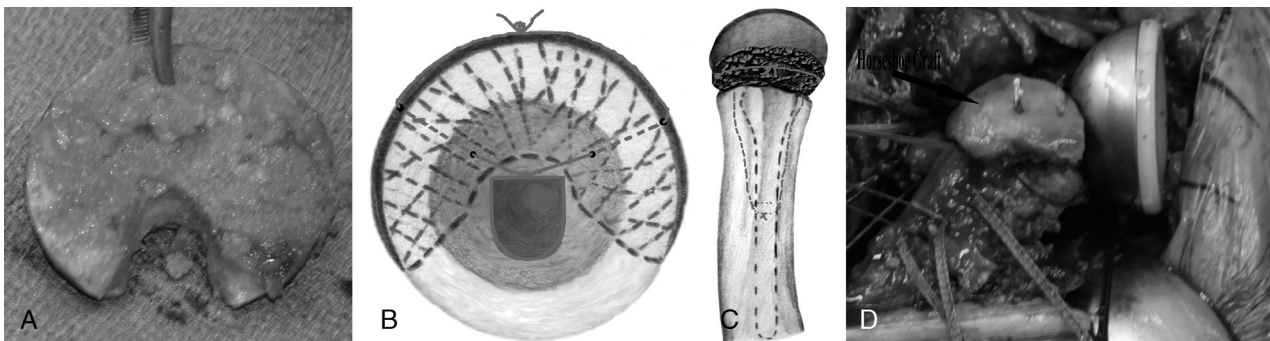


FIGURE 2. Horseshoe graft—A, Humeral head fashioned to shape of horseshoe; B, graft placement seen from axial view, with suture passed around stem and then through 2 drill holes of graft; C, graft placement on lateral surface of prosthesis with suture tied as seen from lateral view; D, graft secured to prosthesis.

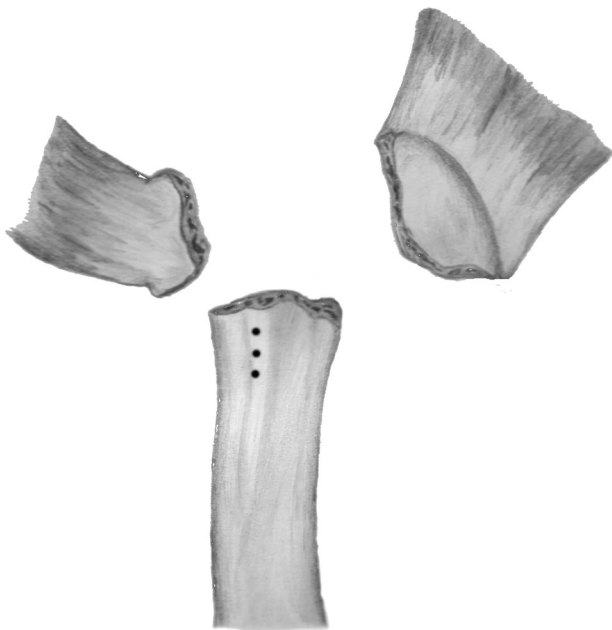


FIGURE 4. Drill holes placed through bicipital groove.

tap. In situations of fractures, the glenoid typically does not have significant wear, and, as such, the version typically follows the glenoid center line.¹⁵ Cannulated reaming is then carried over the centering tap until at least 40% of subchondral bleeding bone is encountered to assist with ingrowth on the baseplate. Once adequately reamed, the tap is removed and the glenoid baseplate is seated. Excellent compression of the baseplate should be achieved, as the 6.5-mm central axis screw compresses the construct against the prepared glenoid surface. The 4 peripheral holes are drilled with attempts at placing locking screws circumferentially.

The decision on the size of the glensphere is typically dictated by the system used and the experience of the surgeon. With the DJO system, multiple glensphere sizes are available. In cases of secure confident fixation of the baseplate, a glensphere that closely matches the anatomic center of rotation of the shoulder is selected. Thus, in men, a 32-mm neutral glensphere is selected, and in smaller women, a 32-mm (-4-mm offset) glensphere is selected. In cases where baseplate fixation is compromised (ie, glenoid fracture or glenoid erosion), a 36-mm glensphere is selected, which has a more medialized center of rotation. Most systems allow for trialing

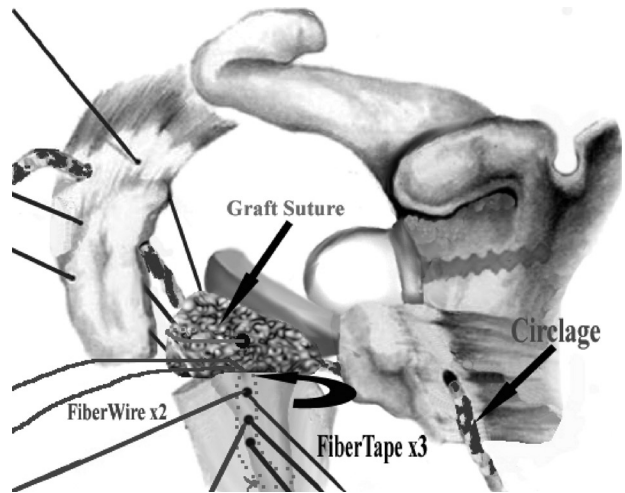
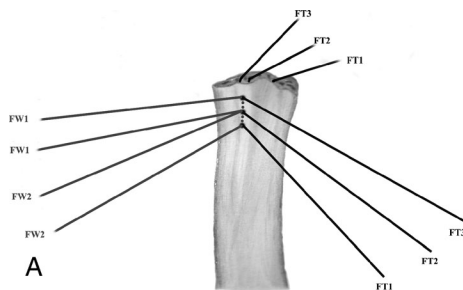


FIGURE 6. Sutures are passed through the bone-tendon junction of the greater and lesser tuberosities.

of the components, which may be useful before selection of the final component. Once the trial or final implant is placed, attention is directed back to the humeral preparation.

Horseshoe Graft Preparation

A horseshoe graft for the humeral component is next prepared (Figs. 2A–D). The humeral head segment is contoured into a horseshoe or U shape (Fig. 2A). A burr is used to remove any articular cartilage down to the subchondral bone. A saw is then used to cut the head into a wedge, and the central cancellous bone is removed. A rongeur can also be useful for this portion. The graft should fit snugly around the undersurface of the reverse shoulder prosthesis stem so that the subchondral bone (previous articular side) is facing laterally. This can be fitted to either the trial or final implant, as the diameter is the same. Two drill holes are made on each limb of the U to allow for passage of a suture that is tied around the stem of the prosthesis (Fig. 2B). The suture can be tied on the back table to the prosthesis and then around the horseshoe graft, or the graft can be secured after the component is cemented (Fig. 2C). By using a graft of this fashion, the greater tuberosity has a larger surface for bone ingrowth around the stem.

Humeral Preparation

The humeral canal is hand reamed to gentle chatter. This is then followed by sequential broaches that serve as humeral stem trials. The stem should be oriented in retroversion of approximately 30 degrees relative to the forearm. In cases where there




FIGURE 5. Suture placement—A, FiberTape (FT) and FiberWire (FW) sutures passed through drill holes of bicipital groove. B, Intraoperative photo of suture placement.

is no metaphyseal extension of the fracture through the calcar, the stem should be impacted down to the level of the medial calcar fracture. In cases where the calcar is attached to the humeral head, the area can be measured directly off the head segment to estimate how proud the stem should be placed (Fig. 3). A useful trick to help maintain stability of the trial is to place a Raytec laparotomy (Johnson & Johnson, New Brunswick, NJ) pad around the trial stem and use this to help maintain the height and rotation of the trial. The humeral socketed trial is then placed, and the shoulder is then reduced to the glenosphere. The tuberosities are gently reduced around the neck of the stem. Stability of the implant should be assessed with the arm in adduction and internal rotation, using an anterior drawer test to ensure stability. Additional stability of the implant will be achieved with tuberosity reconstruction; the implant, therefore, does not have to be placed with significant tension on the soft tissues.

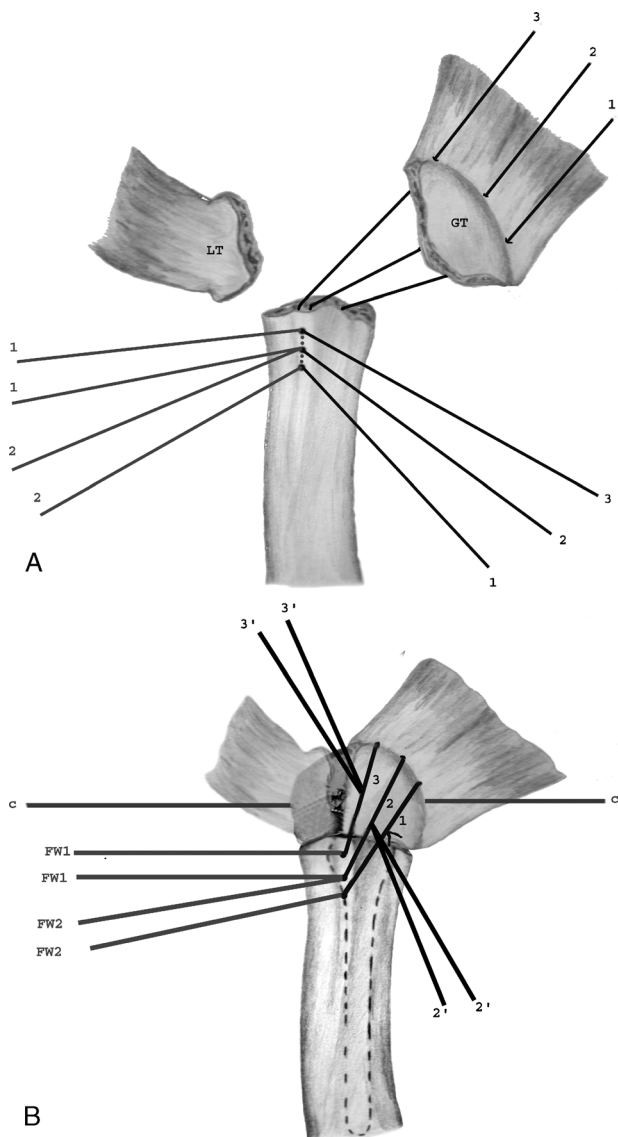


FIGURE 7. Vertical suture fixation of greater tuberosity—A, The 3 vertical FiberTape sutures to the greater tuberosity are passed first. B, Sutures are tied and the tails of 2 of the sutures are saved to allow horizontal fixation to the lesser tuberosity.

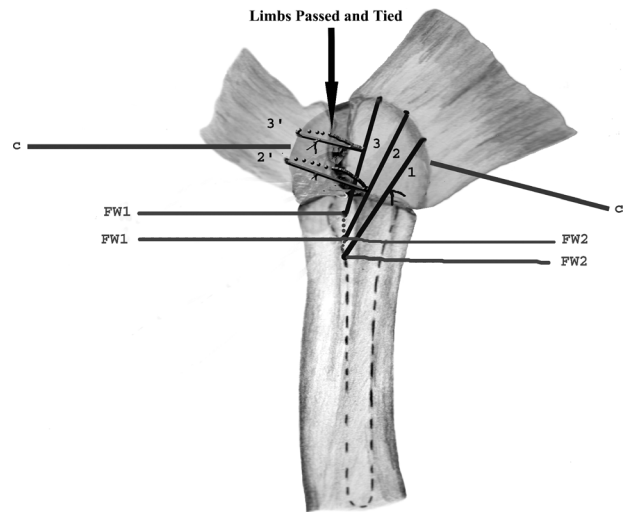


FIGURE 8. One limb of each saved FiberTape tail is passed around bone-tendon junction of lesser tuberosity for horizontal tuberosity fixation.

With satisfactory trialing, the stem is removed. The humeral shaft is drilled to allow for placement of the sutures necessary for fixation of the tuberosities and placement of bone graft. The basic principals of tuberosity fixation, as described by Frankle and Mighell¹⁶ and Frankle et al,¹⁷ are used. This includes the use of horizontal suture fixation between the greater and lesser tuberosities, vertical suture fixation between the humeral shaft and the tuberosities, and a cerclage suture that passes circumferentially around the neck of the prosthesis and then through the greater and lesser tuberosities.

Horizontal fixation is achieved using FiberWire (Arthrex) or FiberTape (Arthrex) sutures placed at the bone-tendon junction of the greater and lesser tuberosities. Cerclage fixation is achieved using a single FiberTape suture passed around the

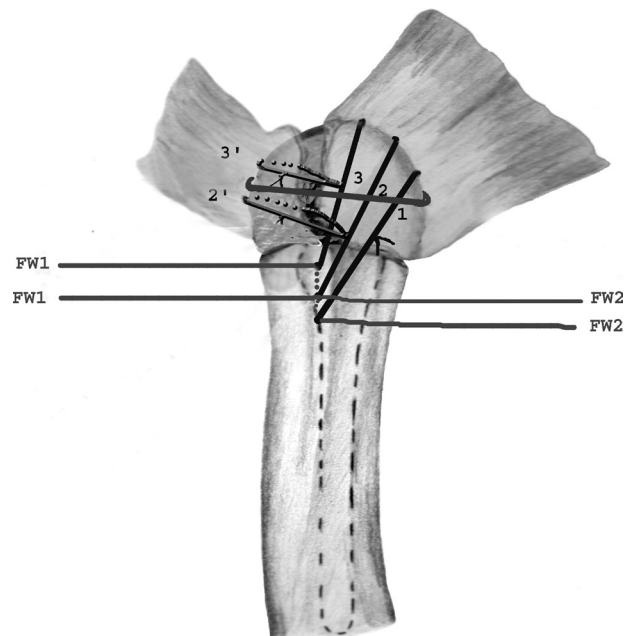


FIGURE 9. Cerclage suture tied.

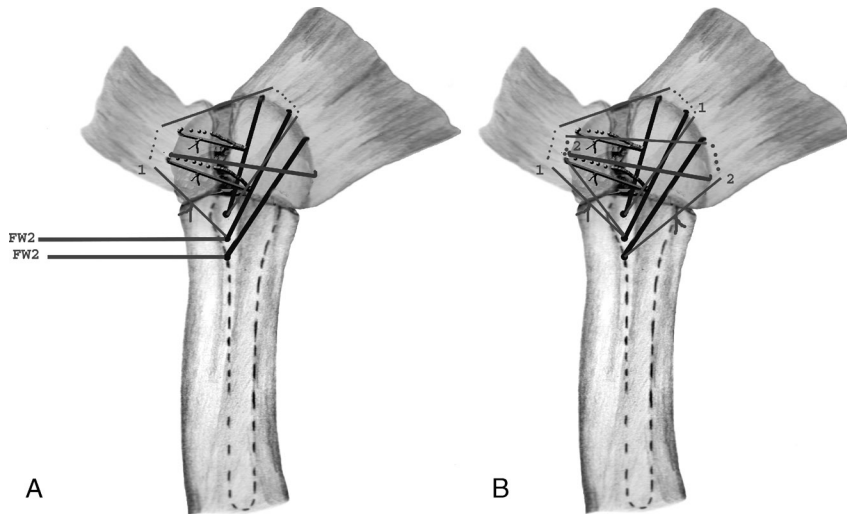


FIGURE 10. Vertical fixation of tuberosities—A, First FiberWire is passed; B, second suture is passed and tied for completed suture repair.

neck of the stem and through the bone-tendon junction of the greater and lesser tuberosities.

Vertical fixation is anchored to the biceps groove, as the strongest bone is located in this area. Three drill holes are placed vertically in this area with a 2.0-mm drill bit (Fig. 4). Placing the drill holes in the biceps groove also serves as a means of reestablishing the appropriate tension on the greater tuberosity. Once the drill holes are made, they are then filled with 3 FiberTape sutures. Two of the holes are also then filled with two no. 2 FiberWire (Arthrex) sutures (Figs. 5A, B). The FiberTape (Arthrex) sutures will serve as vertical fixation for the greater tuberosity alone, and the FiberWire (Arthrex) sutures will be used for the vertical fixation between the greater and lesser tuberosities.

To ensure that the proper retroversion of the stem is achieved, a landmark is marked on the proximal humerus to allow reference during placement of the stem. The stem is assembled on the back table, impacting the Morse taper of the humeral socket to the stem. A FiberWire (Arthrex) suture is tied around the stem in the middle and used to secure the graft to the prosthesis (Figs. 2B, C). The graft can either be attached to the stem on the back table before cementing or placed after the stem is cemented. Once the sutures are appropriately placed, the cement is mixed and the humerus is cemented. We com-

monly use a size 6 stem for most women and a size 7 or 8 stem for most men. The 3 intramedullary limbs of the FiberTape (Arthrex) suture going to the greater tuberosity are wrapped around the inferomedial neck of the prosthesis and then around posteriorly. A cerclage suture is also passed around the inferomedial neck of the stem with the posterior limb for capture of the greater tuberosity and the anterior limb for the lesser tuberosity. Particulate bone graft is then impacted around the most proximal 1 cm of the humeral shaft, displacing any cement in this area. The cement is allowed to completely harden while maintaining proper stem height and version.

Tuberosity Management

All sutures are now passed through the bone-tendon junction of the tuberosities but not tied (Fig. 6). Horizontal, vertical, and cerclage sutures are passed between the greater and lesser tuberosities. The vertical sutures through both tuberosities are placed in a figure-of-eight fashion. These sutures may alternatively be placed as locking sutures into the subscapularis and supraspinatus/infraspinatus when the bone is comminuted. Vertical sutures to the greater tuberosity alone are passed through the greater tuberosity bone-tendon junction.

The greater tuberosity is reduced over the horseshoe graft, and the vertical FiberTape (Arthrex) sutures to the greater

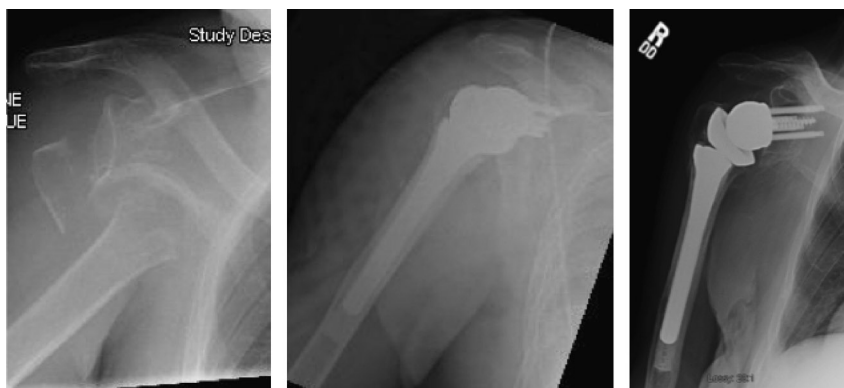

FIGURE 11. A, Initial Grashey radiograph of a 4-part fracture dislocation in a 90-year-old patient. B, Initial postoperative radiograph illustrating anatomic tuberosity repair. C, A 6-month postoperative Grashey radiograph illustrating anatomic tuberosity healing.

tuberosity are tied first to secure the reduction of the greater tuberosity (Fig. 7). Next, the horizontal fixation sutures between the greater and lesser tuberosities are tied. This is done by taking a limb of the suture tail from 2 of the previously tied vertical suture knots and passing one limb from 2 of the knots around the bone tendon interface of the lesser tuberosity. Two limbs are passed in this fashion and then tied (Fig. 8). In effect, 2 of the FiberTape (Arthrex) sutures function for vertical fixation of the greater tuberosity to the shaft and horizontal fixation of the tuberosities to one another. The cerclage suture is tied next (Fig. 9). Lastly, the arm is abducted slightly, and the vertical sutures between the tuberosities are tied (Figs. 10A, B). The rotator cuff interval is then closed with interrupted FiberWire (Arthrex) or Ethibond sutures (Ethicon, Somerville, NJ). The shoulder is moved through a full range of motion to ensure the stability of fracture fixation (Fig. 11).

Rehabilitation

Postoperatively, patients are placed in a shoulder immobilizer. Rigid immobilization of the shoulder is maintained for 4 to 6 weeks or until radiographic evidence of tuberosity healing is demonstrated. Active motions of the elbow, wrist, and hand are initiated immediately. Based on the degree of patient compliance, pendulum exercises may be initiated within 2 weeks. At 6 weeks, the immobilizer is typically discontinued, and active assisted motion of the shoulder is initiated. Formal physical therapy is at the discretion of the physician and not typically started until 4 to 6 weeks postoperatively.

DISCUSSION

Management of complex proximal humeral fractures in the elderly population remains controversial. Based on the unsatisfactory outcomes of open reduction and internal fixation for 3- and 4-part fractures, Neer¹ first advocated the use of hemiarthroplasty as the primary treatment and reported excellent outcomes in more than 90% of his patients. These results, however, have not been consistently replicated, with multiple studies reporting consistently poor outcomes about patient satisfaction and overall function.²⁻⁷ This is especially true for patients older than 70 years, whose functional results of hemiarthroplasty for fracture are statistically worse.^{2,7} Elderly patients are more likely to have poor bone quality and may not have the adequate social structure to support an extensive rehabilitation required after hemiarthroplasty.

In a recent series with the longest clinical follow-up to date (mean, 10.3 years), Antuña et al² reviewed the results of 57 patients treated with hemiarthroplasty for acute shoulder fracture and found that more than half (53%) of the patients were dissatisfied owing to pain or limited motion. Patients older than 70 years performed statistically worse. As a result, some authors have questioned the original recommendation of prosthetic replacement for comminuted fractures.³

Optimal results of hemiarthroplasty are obtained by proper component positioning and anatomic healing of the tuberosities. This type of optimal result can be difficult to achieve in the elderly population, as anatomic healing of the tuberosities can be challenging. A frequent cause of a poor outcome after hemiarthroplasty for fracture relates to malunion or nonunion of the tuberosities. Reasons for tuberosity failure are often multifactorial and include both patient- and surgeon-related factors. Patient factors include age and comorbidities such as smoking or diabetes. Several studies have noted a higher incidence of malunion in patients older than 75 years.^{3,18} This may be attributable to poor bone quality resulting in poor tuberosity su-

ture fixation or secondary to insufficient vascularity creating limited healing potential. Surgeon-related factors are frequent and relate to component malpositioning. The establishment of the proper height and version is of paramount importance and can be extremely challenging in the fracture setting because of lack of normal landmarks. Even in the hands of an experienced upper extremity surgeon, tuberosity malposition can approach 50%.³ Shifting the greater tuberosity inferiorly by as little as 1 cm will significantly increase the glenohumeral joint forces and make it more challenging to elevate the arm.¹⁹ Similarly, placing the stem in an excessive amount of retroversion will prevent the appropriate position of the tuberosity in the horizontal plane and cause excessive tension on the repair when the arm is internally rotated.

When tuberosity malunion, nonunion, or component malpositioning occur, the result is a rotator cuff deficient shoulder. It follows that the reverse shoulder replacement can provide salvage for these situations. The results of reverse arthroplasty in the setting of failed hemiarthroplasty for fracture have shown significant improvements in pain and functional scores in this challenging patient population.²⁰ The hope, however, is to avoid the need for such a salvage operation.

The use of reverse shoulder arthroplasty for acute fracture of the proximal humerus is not a new concept.⁹⁻¹¹ Despite encouraging results reported by several authors, the use of reverse shoulder replacement remains an off-label use not currently approved by the Food and Drug Administration, and all available studies involve small patient populations with limited follow-up. The longest follow-up currently available was reported by Cazeneuve and Cristofari¹⁰ who described 16 patients (mean age, 75 years) treated with the Grammont-style reverse arthroplasty for fracture. At a mean follow-up of 8 years, patients achieved a mean Constant score of 60. Restoration of external rotation was better in cases of tuberosity healing. Radiographs demonstrated inferior notching in 69% of patients. In the largest series to date, Bufquin et al⁹ prospectively evaluated the outcomes of 43 patients (mean age, 78 years) with 3- and 4-part fractures treated with a Grammont-style reverse arthroplasty. With a follow-up of only 22 months, they reported encouraging results, with a mean Constant score of 44 and a mean active elevation of 97 degrees. Complications in this series, however, were frequent and included radiographic scapular notching in 25% of patients and tuberosity displacement in 53% of patients. Restoration of active external rotation was better when the greater tuberosity healed. Most recently, Klein et al¹¹ prospectively reviewed the results of 20 patients (mean age, 75 years) treated with a Grammont-style reverse arthroplasty with a follow-up of 33 months. Using a technique where the tuberosities were excised, patients achieved a mean Constant score of 68 and a mean forward elevation of 123 degrees. In this series, the dislocation rate was 5% (1 patient sustained 2 dislocations).

When using reverse arthroplasty for fracture, one of the main points of contention is about proper management of the tuberosities. Those who routinely resect the tuberosities argue that the rotator cuff is not essential for proper function of a reverse shoulder replacement and that the deltoid function is sufficient.¹¹ Those in favor of preserving the tuberosities argue that preservation of the rotator cuff can help maintain stability and ultimately improve shoulder function. The current authors agree with the latter argument and feel that preservation of the tuberosities is of utmost importance.

Dislocation after reverse shoulder arthroplasty remains one of the most common complications, with published rates as high as 31%.²¹⁻²³ The highest rate of complications, reported by

De Wilde et al,²³ occurred after reconstruction after tumor resection without reconstitution of the proximal humerus. Although tumor resection can routinely involve more extensive dissection and surgical release, this setting can partly mimic the situation after acute fracture when the tuberosities are excised. In addition, the importance of subscapularis integrity has been stressed as a key element of stability and has been the impetus for advocates of the superior approach for this surgery.²⁴ It follows that repair of the tuberosities will contribute to greater stability of the implant in patients treated with reverse arthroplasty for acute fractures. When tuberosity repair is performed, the circumferential stability obtained by the tuberosity repair allows the implant to be seated with decreased soft tissue tension and less resultant humeral lengthening.

When reverse shoulder arthroplasty is performed using a more anatomic center of rotation, it becomes possible to restore near-normal anatomy by repairing the tuberosities. By establishing stability of the glenohumeral joint with a reverse articulation, sufficiently repaired tuberosities will likely have a greater chance of healing. Successful tuberosity healing around a more anatomic reverse shoulder arthroplasty can result in more optimal restoration of rotator cuff function at a more anatomic length-tension relationship of the rotator cuff muscles. Restoration of active internal and external rotations can therefore be expected.

The current technique offers a reproducible way of performing a reverse shoulder replacement for acute proximal humerus fractures in the elderly population. This technique emphasizes secure tuberosity fixation using currently available reverse shoulder prosthetic designs and a horseshoe autograft derived from the head segment. We believe that preservation of the tuberosities is critical to improved function and prosthetic stability, and we advocate this technique of secure tuberosity repair. Additional prospective studies with longer follow-up and larger patient numbers will clarify the specific indications for reverse shoulder replacement after acute proximal humerus fractures.

REFERENCES

1. Neer CS. Displaced proximal humeral fractures. Part II. Treatment of three and four part displacement. *J Bone Joint Surg Am.* 1970; 52(6):1090–1103.
2. Antuña SA, Sperling JW, Cofield RH. Shoulder hemiarthroplasty for acute fractures of the proximal humerus: a minimum five-year follow-up. *J Shoulder Elbow Surg.* 2008;17(2):202–209.
3. Boileau P, Krishnan SG, Tinsi L, et al. Tuberosity malposition and migration: reasons for poor outcomes after hemiarthroplasty for displaced fractures of the proximal humerus. *J Shoulder Elbow Surg.* 2002;11(5):401–412.
4. Zyto K, Wallace WA, Frostick SP, et al. Outcome after hemiarthroplasty for three- and four-part fractures of the proximal humerus. *J Shoulder Elbow Surg.* 1998;7(2):85–89.
5. Anjum SN, Butt MS. Treatment of comminuted proximal humerus fractures with shoulder hemiarthroplasty in elderly patients. *Acta Orthop Belg.* 2005;71(4):388–395.
6. Kraulis J, Hunter G. The results of prosthetic replacement in fracture-dislocations of the upper end of the humerus. *Injury.* 1976;8(2):129–131.
7. Goldman RT, Koval KJ, Cuomo F, et al. Functional outcome after humeral head replacement for acute three- and four-part proximal humeral fractures. *J Shoulder Elbow Surg.* 1995;4(2):81–86.
8. Hasan SS, Leith JM, Campbell B, et al. Characteristics of unsatisfactory shoulder arthroplasties. *J Shoulder Elbow Surg.* 2002;11(5):431–441.
9. Bufquin T, Hersan A, Hubert L, et al. Reverse shoulder arthroplasty for the treatment of three- and four-part fractures of the proximal humerus in the elderly: a prospective review of 43 cases with a short-term follow-up. *J Bone Joint Surg Br.* 2007;89(4):516–520.
10. Cazeneuve JF, Cristofari DJ. Grammont reversed prosthesis for acute complex fracture of the proximal humerus in an elderly population with 5 to 12 years follow-up. *Rev Chir Orthop Reparatrice Appar Mot.* 2006;92(6):543–548.
11. Klein M, Juschka M, Hinkenjann B, et al. Treatment of comminuted fractures of the proximal humerus in elderly patients with the Delta III reverse shoulder prosthesis. *J Orthop Trauma.* 2008; 22(10):698–704.
12. Visser CP, Coene LN, Brand R, et al. Nerve lesions in proximal humeral fractures. *J Shoulder Elbow Surg.* 2001;10(5):421–427.
13. McLaughlin JA, Light R, Lustrin I. Axillary artery injury as a complication of proximal humerus fractures. *J Shoulder Elbow Surg.* 1998;7(3):292–294.
14. Neer CS. Four-segment classification of proximal humeral fractures: purpose and reliable use. *J Shoulder Elbow Surg.* 2002;11(4):389–400.
15. Bicos J, Mazzocca A, Romeo AA. The glenoid center line. *Orthopedics.* 2005;28(6):581–585.
16. Frankle MA, Mighell MA. Techniques and principles of tuberosity fixation for proximal humeral fractures treated with hemiarthroplasty. *J Shoulder Elbow Surg.* 2004;13(2):239–247.
17. Frankle MA, Ondrovic LE, Markee BA, et al. Stability of tuberosity reattachment in proximal humeral hemiarthroplasty. *J Shoulder Elbow Surg.* 2002;11(5):413–420.
18. Grönhagen CM, Abbaszadegan H, Révay SA, et al. Medium-term results after primary hemiarthroplasty for comminute proximal humerus fractures: a study of 46 patients followed up for an average of 4.4 years. *J Shoulder Elbow Surg.* 2007;16(6):766–773.
19. Huffman GR, Itamura JM, McGarry MH, et al. Biomechanical assessment of inferior tuberosity placement during hemiarthroplasty for four-part proximal humeral fractures. *J Shoulder Elbow Surg.* 2008;17(2):189–196.
20. Levy J, Frankle M, Mighell M, et al. The use of the reverse shoulder prosthesis for the treatment of failed hemiarthroplasty for proximal humeral fracture. *J Bone Joint Surg Am.* 2007;89(2): 292–300.
21. Wall B, Nové-Josserand L, O'Connor DP, et al. Reverse total shoulder arthroplasty: a review of results according to etiology. *J Bone Joint Surg Am.* 2007;89(7):1476–1485.
22. Werner CM, Steinmann PA, Gilbert M, et al. Treatment of painful pseudoparesis due to irreparable rotator cuff dysfunction with the Delta III reverse-ball-and-socket total shoulder prosthesis. *J Bone Joint Surg Am.* 2005;87(7):1476–1486.
23. De Wilde L, Sys G, Julien Y, et al. The reversed delta shoulder prosthesis in reconstruction of the proximal humerus after tumour resection. 2003;69(6):495–500.
24. Seebauer L. Total reverse shoulder arthroplasty: European lessons and future trends. *Am J Orthop.* 2007;36(12 suppl 1):22–28.